

Your Practice Online

P R E S E N T S

Common Toe Deformities

Multimedia Health Education

Disclaimer

This movie is an educational resource only and should not be used to manage Orthopaedic Health. All decisions about Toe Deformities must be made in conjunction with your Physician or a licensed healthcare provider.

Australia

Dr. Prem Lobo
G.P.O Box No.635
SYDNEY NSW- 2001

Phone: 1 800 883 260
Fax: +61 2 9475 1036
Email: info@yourpracticeonline.com.au

USA

Holly Edmonds RN, CLNC
1006 Triple Crown Drive
Indian Trail, NC 28079

Toll Free: 1 877 388 8569 (Toll Free)
Fax: 1 704 628 0233
Email: info@yourpracticeonline.net

New Zealand

Greg Eden
P O Box 17 340 Greenlane
Auckland 1130

Phone: +09 974 9839
Fax: +64 9 634 6282
Email: info@yourpracticeonline.co.nz

WWW.YOURPRACTICEONLINE.NET

Your Practice Online

MULTIMEDIA HEALTH EDUCATION MANUAL

TABLE OF CONTENTS

SECTION	CONTENT	PAGE
1 . Introduction		
	a. Introduction	
	b. Normal Foot Anatomy	
2 . Toe Deformities		
	a. Introduction	
	b. Causes	
	c. Signs & Symptoms	
	d. Conservative Treatment	
3 . Surgical Procedure		
	a. Introduction	
	b. Surgical Treatment	
	c. Post Operative Care	
	d. Risks and Complications	

INTRODUCTION

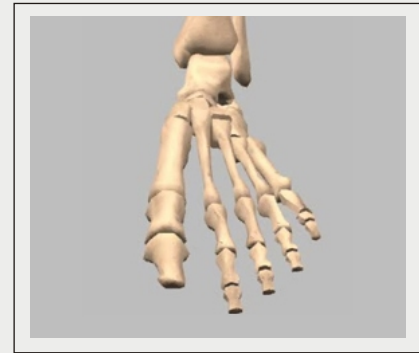
The foot and ankle in the human body work together to provide balance, stability, movement, and propulsion.

Introduction

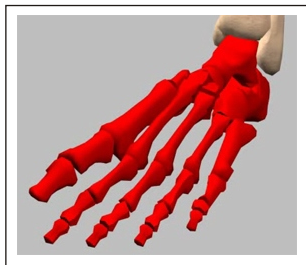
The foot and ankle in the human body work together to provide balance, stability, movement, and propulsion.

This complex anatomy consists of:

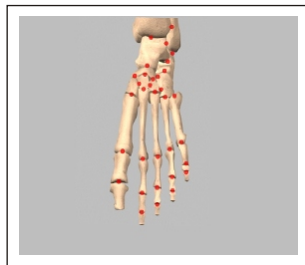(Refer fig.1& fig. "a to f")



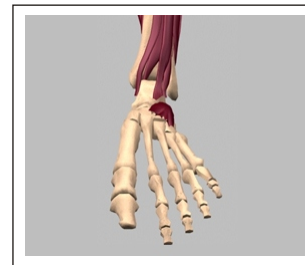(Fig.1)



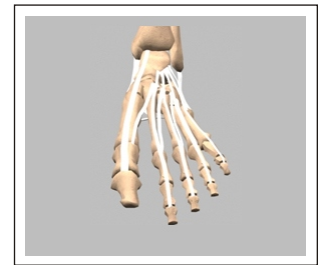
a. 26 bones



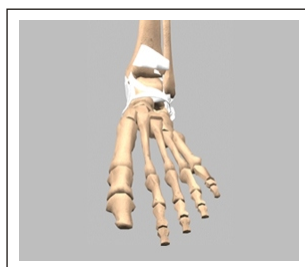
b. 23 joints



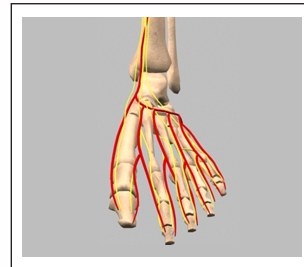
c. Muscles



d. Tendons



e. Ligaments



f. Blood Vessels, Nerves, and Soft Tissue

Normal Foot Anatomy

The foot can be divided into three anatomical sections called the hind foot, mid foot, and Forefoot. For this module we will focus on the forefoot to understand normal toe anatomy and its supporting structures.

The forefoot consists of your toe bones, called phalanges, and metatarsal bones, the long bones in your feet.

Phalanges connect to metatarsals at the ball of the foot by joints called phalange metatarsal joints.

(Refer fig. 2)

Each toe has 3 phalange bones and 2 joints, while the big toe contains two phalange bones, two joints, and two tiny, round sesamoid bones that enable the toe to move up and down. Sesamoid bones are bones that develop inside of a tendon over a bony prominence.

(Refer fig. 3)

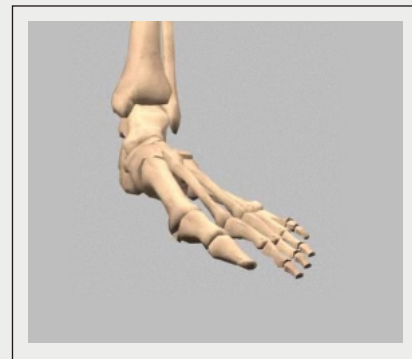The first metatarsal bone connected to the big toe is the shortest and thickest of the metatarsals and is the location for the attachment of several tendons. This bone is important for its role in propulsion and weight bearing.

(Refer fig. 4)

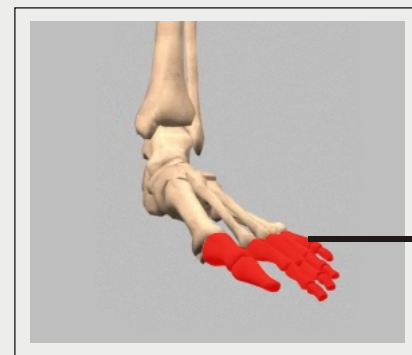
Soft Tissue Anatomy

Our feet and ankle bones are held in place and supported by various soft tissues.

(Refer fig. 5)

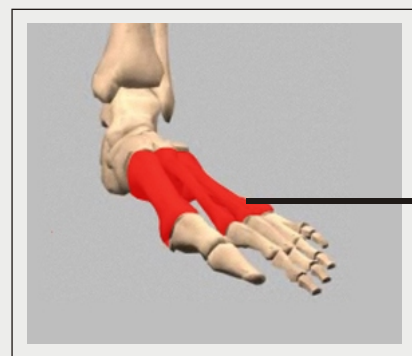


(Fig.2)



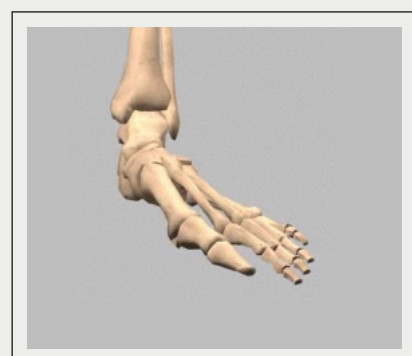● Phalanges

(Fig.3)



● Metatarsals

(Fig.4)



(Fig.5)

Unit 1:

Introduction

Cartilage

Shiny and smooth, cartilage allows smooth movement where two bones come in contact with each other.

(Refer fig. 6)

Tendons

Tendons are soft tissue that connects muscles to bones to provide support.

(Refer fig. 7)

Ligaments

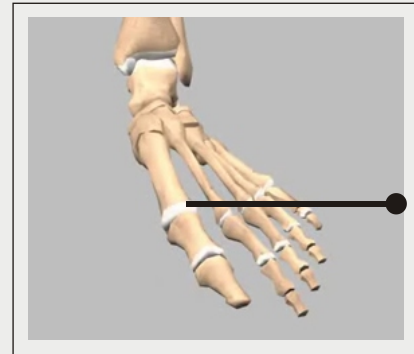
Ligaments are strong rope like tissue that connects bones to other bones and help hold tendons in place providing stability to the joints. The plantar fascia is the longest ligament in the foot, originating at the calcaneus, heel bone, and continuing along the bottom surface of the foot to the forefoot. It is responsible for the arches of the foot and provides shock absorption.

(Refer fig. 8)

Muscles

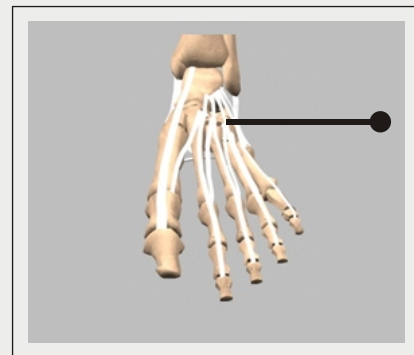
Muscles are fibrous tissue capable of contracting to cause body movement. There are 20 muscles in the foot and these are classified as intrinsic or extrinsic. The intrinsic muscles are those located in the foot and are responsible for toe movement. The extrinsic muscles are located outside the foot in the lower leg. The gastrocnemius or calf muscle is the largest of these and assists with movement of the foot.

(Refer fig. 9)



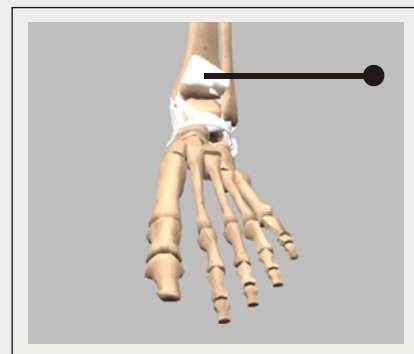
Cartilage

(Fig.6)



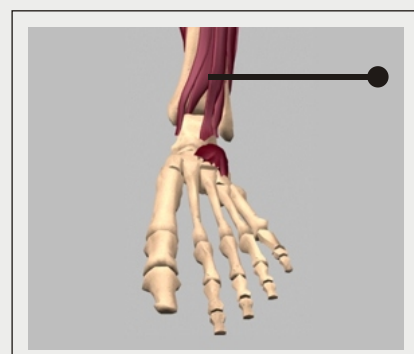
Tendons

(Fig.7)



Ligaments

(Fig.8)



Muscles

(Fig.9)

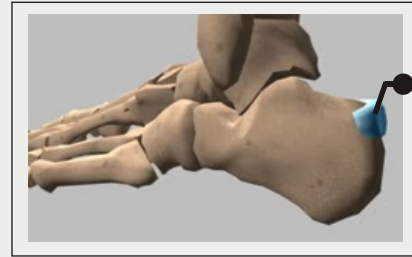Unit 1:

Introduction

Bursae

Bursae are small fluid filled sacs that decrease friction between tendons and bone or skin. Bursae contain special cells called synovial cells that secrete a lubricating fluid. When this fluid becomes infected, a common painful condition known as Bursitis can develop.

(Refer fig. 10)



Bursae

(Fig. 10)

Unit 2:

Toe Deformities

Toe Deformities - Introduction

Deformities of the toes can have a negative impact on one's quality of life, especially if left untreated. Walking can become very painful and properly fitted shoes may be difficult to find due to abnormal alignment of the toes. As your ability to walk comfortably lessens, a sedentary lifestyle sets in with its associated health risks. Untreated toe deformities may also lead to problems with other weight bearing joints such as the knees and hips.

Toe Deformities - Causes

Causes of toe deformities include the following:

- Congenital
- Improperly Fitted Shoes
- Injury
- Muscle and Nerve Damage

Congenital :

Babies can be born with existing toe deformities such as in muscular dystrophy cases.

Improperly Fitted Shoes :

Shoes that are too small cause the toes to be positioned abnormally and can lead to deformities. Shoes with a narrow toe area and high heeled shoes can lead to the same problem.

Injury :

Trauma to the toe such as with a fracture or “jamming” the toe can also lead to deformities.

Muscle and Nerve Damage :

Certain diseases affecting muscle and nerve function can cause ligaments and tendons to tighten leading to a deformity. This can occur with Diabetics, alcoholics, stroke victims, and patients with osteoarthritis and rheumatoid arthritis.

Toe Deformities - Signs and Symptoms

The most common toe deformities are Hammer toes, Claw toes, and Mallet toes.

All three share the following symptoms:

- Pain with ambulation while wearing shoes
- Difficulty finding properly fitted and comfortable shoes
- Painful corns and calluses : These are hard skin growths that result from pressure and rubbing from ill-fitting footwear
- Initially, the deformed toe is flexible. If left untreated however, it will become fixed and immovable requiring surgery.

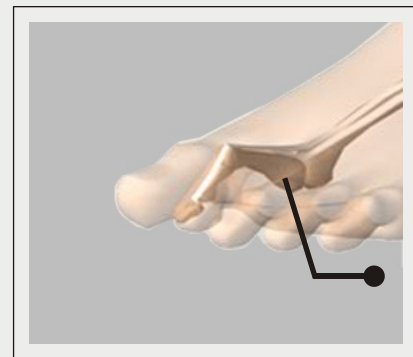
Although symptoms are similar, the appearance of each type of deformity is different.

- Hammer Toes
- Claw Toe
- Mallet Toe

Hammer Toes :

With this deformity, the toe is bent at the middle joint causing a curling of the toe. It is most common in the second toe, but can occur in any toe. Hammer toes are often present along with a bunion, a painful outgrowth along the side of the foot at the base of the big toe.

(Refer fig. 11)



Hammer Toes
(Fig. 11)

Unit 2:

Toe Deformities

Claw Toe :

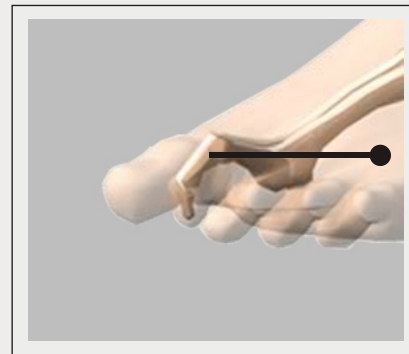This type of deformity involves an upward bending of the toe joint at the ball of the foot. At the middle joint and sometimes the end joint as well, the toes bend downward in a claw-like fashion, often digging in to the sole of the foot. It can occur in any toe except the big toe.

(Refer fig. 12)

Mallet Toe :

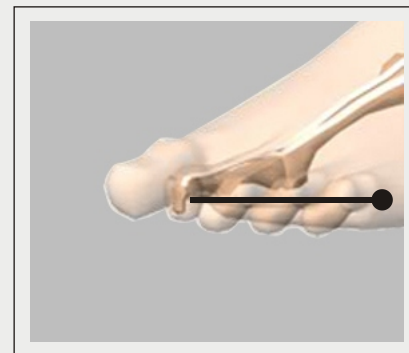This deformity is very similar to a hammer toe except the joint involved is the upper joint instead of the middle joint, giving the toe a mallet-like appearance at the end of the toe.

(Refer fig. 13)



Claw Toe

(Fig. 12)



Mallet Toe

(Fig. 13)

Toe Deformities - Conservative Treatment

Your physician will be able to diagnose your condition by examining the toes. No diagnostic tests are usually necessary unless your physician suspects nerve involvement in which case special tests may be ordered.

Conservative treatment measures are usually recommended before surgery is considered. The goals of conservative treatment include:

- Restore or maintain walking ability
- Pain Relief
- Decrease pressure and friction over bony prominences
- Delay the progression of the deformity

Your physician will assess your condition and may suggest the following treatments:

- New shoes with a soft, high, enlarged toe area.
- Avoid tight, narrow, and high heeled shoes.
- Splints or tape may be applied to reposition the toes.
- Cushions or pads applied to pressure areas to relieve pain and prevent skin breakdown.
- Toe exercises may also be prescribed. These can include picking up marbles with your toes, crumbling a piece of paper with your toes and other stretching exercises.

Surgical Procedure

Introduction:

Surgical treatment of toe deformities may be recommended by your physician if conservative treatment measures fail to relieve your symptoms or if the toes are in a rigid, fixed and immovable position.

The goals of surgery are to restore normal toe alignment and return the foot to normal pain-free function.

Surgical Treatment :

Surgery to correct toe deformities is performed in a hospital operating room under local anesthesia with regional pain blocks and usually does not require an overnight hospital stay.

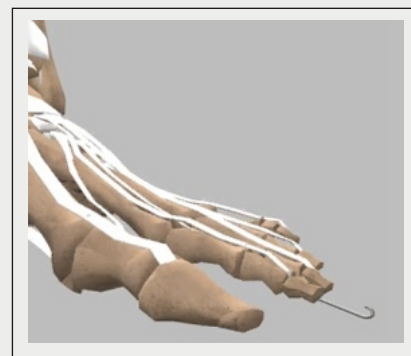
The type of surgery performed on toe deformities depends on certain factors. Your surgeon will consider the following:

- Age
- Extent of the deformity
- Medical history
- Physical condition
- Rigidity or flexibility of the toe

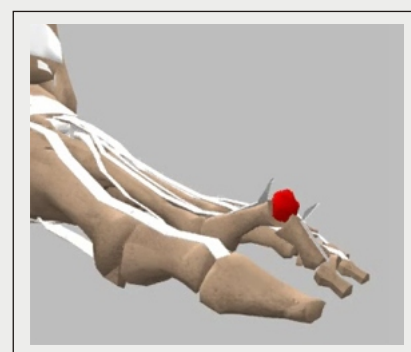
Surgical Procedure

If some flexibility exists in the toe, your surgeon will make an incision over the deformed toe joint and realign the tendons and ligaments. Pins may be placed to keep the toe in position while healing. The incision will then be closed with sutures and covered with a sterile dressing.

If the toe deformity is rigidly fixed, your surgeon will make the incision over the joint of the deformity, realign the tendons and ligaments, and also perform an osteotomy which is the removal of bone pieces. Your surgeon will then insert pins to keep the toes in proper alignment during the healing process.



(Fig. 14)



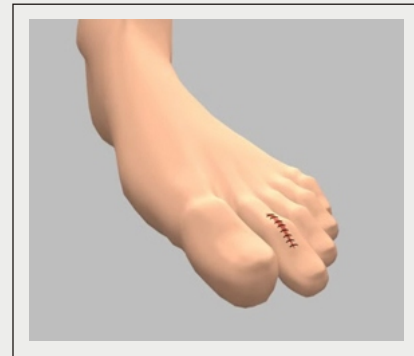(Fig. 15)

Unit 3:

Surgical Procedure

The incision will then be closed with sutures and covered with a sterile dressing.

(Refer fig. "14 to 16")



(Fig. 16)

Surgical Procedure - Post Operative Care

After surgery your surgeon will give you guidelines to follow depending on the type of repair performed and the surgeon's preference. Common Post-operative guidelines include:

- A special post-op shoe will be worn to keep the toes from bending. This can be worn for 2-6 weeks depending on the extent of your surgery.
- You will have a dressing over the surgery site that your surgeon will remove after about a week.
- It is important to keep the dressing clean and dry. No showering or bathing until your surgeon allows.
- Sutures are usually removed at 10-14 days unless dissolvable sutures were used in the surgery.
- Elevating the foot above heart level when sitting and applying ice packs will help to reduce swelling.
- Medications for pain will be prescribed to keep you comfortable.
- Eating a healthy diet and not smoking will promote healing.

Risks and Complications

As with any major surgery there are potential risks involved. The decision to proceed with the surgery is made because the advantages of surgery outweigh the potential disadvantages.

It is important that you are informed of these risks before the surgery takes place.

Complications can be medical (general) or specific to toe surgery.

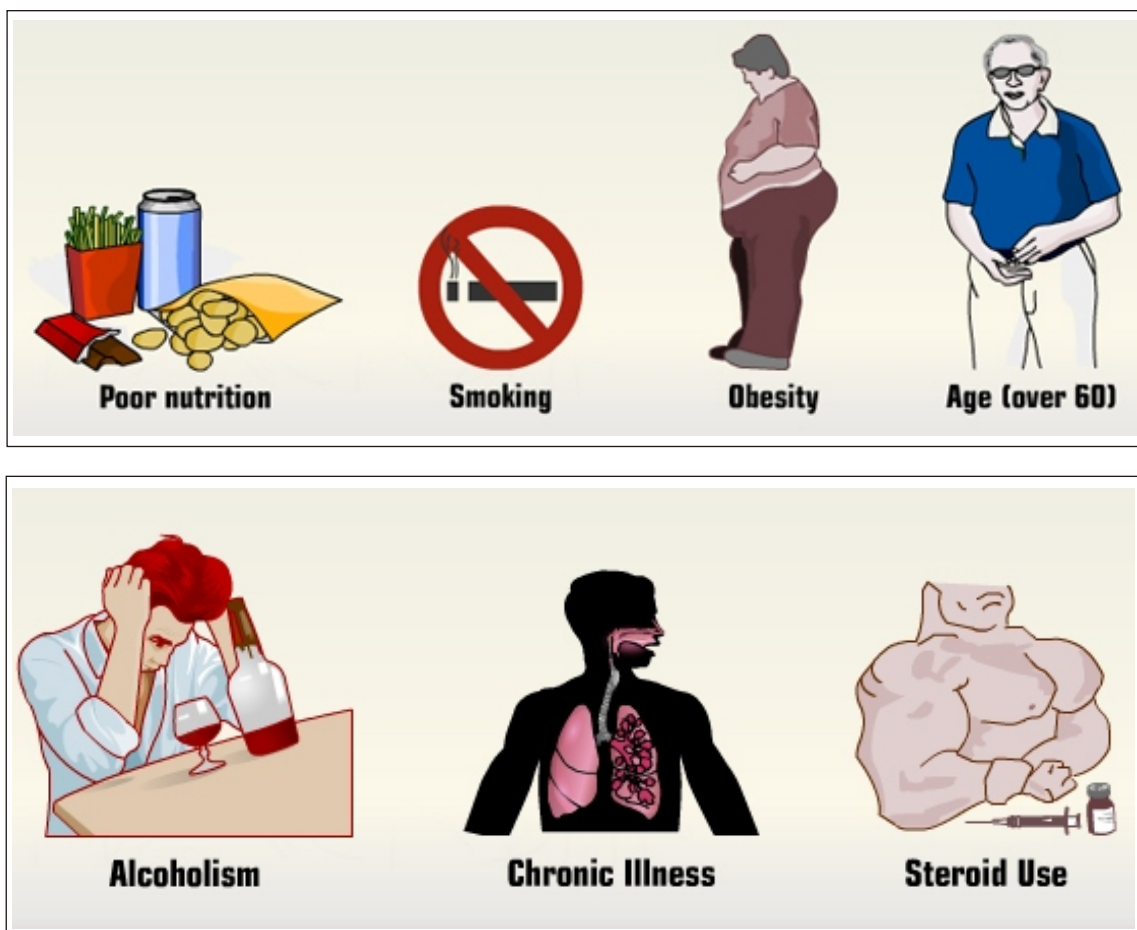
Medical complications include those of the anesthetic and your general well being. Almost any medical condition can occur so this list is not complete. Complications include:

- Allergic reactions to medications
- Blood loss requiring transfusion with its low risk of disease transmission
- Heart attacks, strokes, kidney failure, pneumonia, bladder infections
- Complications from nerve blocks such as infection or nerve damage
- Serious medical problems can lead to ongoing health concerns, prolonged hospitalization, or rarely death.

The majority of patients suffer no complications following surgical correction of toe deformities, however, complications can occur following foot surgery and include:

- Infection
- Nerve damage causing numbness to the skin over the toe area.
- Inadequate correction of the deformity
- Loss of blood supply to the toe
- Stiffness of the toe

Risk factors that can negatively affect adequate healing after foot surgery include:



(Fig. 17)

YOUR SURGERY DATE

READ YOUR BOOK AND MATERIAL

VIEW YOUR VIDEO / CD / DVD / WEBSITE

PRE - HABILITATION

ARRANGE FOR BLOOD

MEDICAL CHECK UP

ADVANCE MEDICAL DIRECTIVE

PRE - ADMISSION TESTING

FAMILY SUPPORT REVIEW

Physician's Name : _____

Patient's Name : _____

Physician's Signature: _____

Patient's Signature: _____

Date : _____

Date : _____